The nurse is preparing to administer a first dose of losartan to a 38-year-old client.

Which finding would be **most** concerning to the nurse?

1. Blood pressure of 142/86 mmHg
2. Client also takes furosemide daily
3. Client says her menstrual period is late
4. History of dry cough when taking lisinopril

Incorrect

Credit	0 / 1
Answered Correctly	33%
Scoring Rule	0 / 1 Scoring
Time Spent	00:18

Explanation

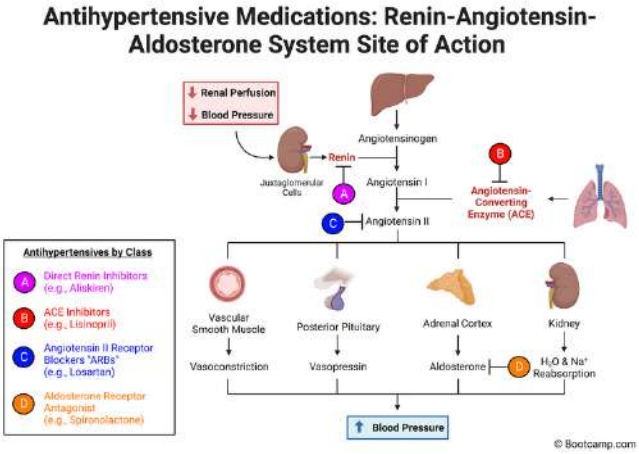

Angiotensin II receptor blockers (ARBs) (e.g., losartan, valsartan) are indicated to treat **hypertension and heart failure**. They act by blocking the effects of angiotensin II on vascular smooth muscle and the adrenal glands (blocks effects of aldosterone), preventing activation of the **renin-angiotensin-aldosterone system (RAAS)**.

Contraindications to ARBs include allergy, **pregnancy**, and lactation. All RAAS medications (e.g., lisinopril) are teratogenic, and ARBs carry a **black box warning** regarding pregnancy because they

The nurse is caring for a client who is receiving a high dose of methimazole.

When evaluating the client for a potentially life-threatening side effect related to the medication, it would be a **priority** for the nurse to report

1. dizziness
2. sore throat ✓
3. pulse of 58
4. 4/10 joint pain ✗

Incorrect

Credit	0 / 1
Answered Correctly	42%
Scoring Rule	0 / 1 Scoring
Time Spent	00:20

Explanation

Methimazole is an antithyroid drug used to treat **hyperthyroidism** (Graves' disease) and to **suppress thyroid function** in preparation for radioactive iodine therapy or thyroidectomy. Methimazole **inhibits thyroid hormone synthesis** by inhibiting the incorporation of iodine into tyrosine, which are precursors for T_3 and T_4.

Agranulocytosis is **severe neutropenia**, which is the most dangerous side effect of methimazole therapy and occurs when methimazole **suppresses bone marrow production of leukocytes**, greatly increasing the risk for developing a **life-threatening infection**. A **sore throat or fever** are usually the **first signs of an infection** and should be reported immediately, followed by discontinuation of methimazole and reversal of agranulocytosis **[Choice 2]**.

Incorrect:

Dizziness
Dizziness is a transient side effect that may occur in some individuals, and precautions should be taken to *ensure client safety.* Early detection of agranulocytosis takes precedence to *prevent progression of the infection.*

Pulse 58

The nurse is teaching a client with a urinary tract infection who is receiving newly prescribed phenazopyridine.

Which of the following statements by the client would indicate a correct understanding of the teaching?

1. ~~"Taking this medication will make urinating less painful."~~
2. "I will call my healthcare provider right away if I experience reddish-orange urine."
3. "I will need to continue taking this medication even if my urinary symptoms improve."
4. "Phenazopyridine works by killing the bacteria that causes the urinary tract infection."

Incorrect

Credit	0 / 1
Answered Correctly	Collecting data...
Scoring Rule	0 / 1 Scoring
Time Spent	01:03

Explanation

Urinary analgesics, such as phenazopyridine, **alleviate dysuria** (i.e., painful urination) caused by urinary tract infections (UTIs).

Teaching was effective if the following teaching points are understood:

- **Urinary analgesics (e.g., phenazopyridine) relieve dysuria** caused by UTIs by providing an analgesic effect to the lining of the urinary tract **[Choice 1]**. Therefore, urinary analgesics are often taken with antibiotics (e.g., nitrofurantoin, trimethoprim/sulfamethoxazole) to manage UTI symptoms.

Corrected teaching:

- Metabolism of phenazopyridine causes **urine** to turn an **orange or reddish-orange color [Choice 2]**. Although the nurse should mention that the discoloration can stain clothing, it is **not** necessary to notify the healthcare provider as this is an expected finding that is **harmless and temporary.**
- Clients should **stop taking** phenazopyridine when **dysuria subsides [Choice 3]**. This differs from antibiotic treatments for UTIs, which require clients to complete the full course of treatment regardless of symptom improvement.
- Phenazopyridine relieves dysuria caused by UTIs. It can **not treat the infection** because it has no antibacterial properties **[Choice 4]**. **Antibiotics** (e.g., nitrofurantoin, sulfamethoxazole/trimethoprim) are used to kill the bacteria responsible for UTIs.

The nurse is caring for a client taking nifedipine for hypertension and chronic stable angina.

Which finding is **most** concerning?

1. Facial flushing
2. Pulse rate of 122
3. 3/10 frontal headache
4. Trace edema in the upper extremities

Incorrect

Credit	0 / 1
Answered Correctly	37%
Scoring Rule	0 / 1 Scoring
Time Spent	00:40

Explanation

Calcium channel blockers (CCBs) (e.g., nifedipine, amlodipine) are indicated for **hypertension and prevention of angina**. They **inhibit the influx of calcium** into the myocardial and vascular smooth muscle cells, causing **vasodilation** of coronary and peripheral arteries. Because nifedipine lowers blood pressure, it activates baroreceptors that cause the heart to compensate by increasing its rate. Since nifedipine has no negative inotropic effects, the rate goes unchecked **(reflex tachycardia)**, which can increase cardiac workload and possibly precipitate **angina** and arrhythmias **[Choice 2]**.

Incorrect:

Facial flushing
This is an expected adverse effect of CCBs due to superficial vasodilation and is not as concerning as tachycardia which can increase cardiac workload.

3/10 frontal headache
Headache is an expected side effect of CCBs due to cerebral vasodilation. If it becomes severe, the healthcare provider should be notified. A pain level of 3/10 is not considered severe.

Trace edema in upper extremities
Vasodilating effects of CCBs can cause peripheral edema as a side effect, especially in the lower extremities. A trace amount of edema can usually be managed by lowering the dose or adding a diuretic and is not immediately concerning.

Key Takeaway:

- Clients taking nifedipine should be monitored closely for reflex tachycardia that could increase cardiac workload and precipitate angina.

The nurse is caring for an 84-year-old client who has experienced an allergic reaction to IV dressing tape with redness, edema, vesicles, and pruritus.

Which prescription should the nurse **question**?

1. Oral prednisone
2. Oral hydroxyzine
3. Topical corticosteroids
4. Topical diphenhydramine cream

The nurse has taught a caregiver about caring for a client with Parkinson disease who is being treated with levodopa-carbidopa.

Which of the following statements by the client's caregiver would indicate a correct understanding of the teaching?

1. ~~"I should expect hallucinations as a medication side effect."~~
2. "I will provide the client with slip-on shoes to reduce fall risk."
3. "I will provide protein at every meal to maintain muscle strength."
4. "I should call the health care provider if the client has a flat affect."

The nurse is preparing to administer intranasal desmopressin to a client with diabetes insipidus.

It would be **most** important for the nurse to monitor the client for

1. nasal congestion
2. ✓ altered mental status
3. decreased urine output
4. ✗ low serum sodium level

Explanation

Desmopressin (vasopressin) is a synthetic form of **antidiuretic hormone** (ADH) primarily used to treat **diabetes insipidus** (DI). In DI, the kidneys cannot conserve water due to a **lack of ADH**, which causes **polyuria and dehydration**. Desmopressin treats DI by **increasing water reabsorption** in the kidneys, decreasing the excessive urine output.

Desmopressin can cause **water intoxication** and **hyponatremia** if water retention is excessive and dilutes the blood. Hyponatremia can cause **headache, nausea, vomiting, and muscle cramps**; severe cases may result in **altered mental status, seizures, or coma**. Therefore, monitoring for signs of water intoxication, particularly **altered mental status**, is essential for a client receiving desmopressin **[Choice 2]**.

The nurse is caring for a client who is undergoing an amniotomy.

Which of the following findings would require follow-up?

1. Blood-colored amniotic fluid
2. Fetal station changes from 0 to +1
3. Early fetal heart rate decelerations
4. White specks present in amniotic fluid

Incorrect

Credit	0 / 1
Answered Correctly	52%
Scoring Rule	0 / 1 Scoring
Time Spent	00:46

Explanation

During an **amniotomy**, the amniotic sac is punctured with a plastic hook. This allows amniotic fluid to drain and the fetal head to descend in the pelvis (engagement), promoting **cervical dilation and labor progression**.

Amniotic fluid should be **colorless and without strong odor**. **Bloody amniotic fluid could indicate placental abruption**, premature placental separation from the uterine wall **[Choice 1]**. Abruption prematurely separates maternal and fetal circulation, which deprives the fetus of oxygen and can cause intrauterine fetal demise. The nurse should assess fetal heart rate (FHR), monitor blood loss, and notify the health care provider immediately.

Incorrect:

Fetal station changes from 0 to +1
A +1 fetal station indicates fetal descent into the birth canal, a sign of labor progression, and an *expected* finding following amniotomy.

Early decelerations
As delivery approaches, contractions compress the engaged fetal head. Head compression stimulates the vagus nerve and slows FHR, resulting in early decelerations, an expected finding. Following amniotomy, the gush of amniotic fluid can cause umbilical cord prolapse; therefore, the nurse should assess FHR immediately after rupture. If *variable* or *prolonged* decelerations occur, the nurse should perform a pelvic exam to assess for the umbilical cord.

White specks in amniotic fluid
White specks are anticipated and indicate vernix, a white, cheesy coating that insulates and protects the newborn's skin. Green-stained amniotic fluid indicates meconium and would be concerning for meconium aspiration syndrome.

Key Takeaway:

- Amniotic fluid should be colorless and without strong odor.
- Bloody amniotic fluid suggests placental abruption and requires immediate follow-up.

Place the client in Trendelenburg, Provide a wedge under the left hip

Trendelenburg, modified Sims, and knee-chest position use gravity to reduce umbilical cord compression and prevent further pelvic engagement by the presenting part. Placing a wedge under the left or right hip shifts the uterine weight and reduces vena cava compression, maximizing uteroplacental blood flow and improving FHR. Although these are important interventions, the priority is relieving cord compression to allow adequate fetal oxygenation through the umbilical cord.

Nurses' Notes

1100: Client is 39 weeks pregnant and laboring. Baseline fetal heart rate 130. History of polyhydramnios this pregnancy.

1230: Cervix is 3 centimeters dilated, 50% effaced. The fetal station is -1. Membranes spontaneously ruptured and fetal heart rate is now 95 with minimal variability.

The nurse is caring for a client who is 39 weeks pregnant and experiencing regular uterine contractions every 4-5 minutes. The nurse reviews the Nurses' Notes from 1100 and 1230.

Which of the following interventions should the nurse perform **first**?

1. Place the client in Trendelenburg
2. Provide a wedge under the left hip
3. Notify the health care provider of the fetal heart rate
4. Insert fingers into the vagina and assess for the presenting part

Health History

0730: A 17-year-old client is being seen at the obstetrician's office at 31 weeks gestation. She expresses feeling constant, mild lower abdominal cramps. Client experienced diarrhea yesterday evening and had bright pink vaginal spotting this morning after exercising. Client described an episode of urinary incontinence yesterday morning.

The nurse is caring for a pregnant client and reviews the Health History from 0730.

Drag words from the choices below to fill in the blank in the following sentence.

The nurse knows the client is **most** likely experiencing placenta previa .

Word Choices
✓ preterm labor
✗ gastroenteritis
✗ weakened pelvic floor

The nurse is caring for four postpartum clients.

Which of the following clients should the nurse see **first**?

1. ~~Client who delivered 1 day ago experiencing scant reddish-brown purulent lochia~~
2. Client who delivered 1 hour ago experiencing moderate vaginal bleeding and is receiving oxytocin IV
3. Client who delivered 8 hours ago experiencing increased vaginal bleeding while breastfeeding
4. ~~Client who delivered 12 hours ago who experienced a gush of vaginal blood while ambulating for the first time~~

The nurse assesses the Vital Signs of a postpartum client who gave birth 6 hours ago.

Which intervention should the nurse perform **first**?

1. Apply ice packs to the client's head and neck.
2. Recheck the client's temperature in 30 minutes.
3. Fill the client's water pitcher and encourage her to drink.
4. Obtain an order for a complete blood count and blood cultures.

A client with bladder cancer had surgical placement of a ureteroileostomy (ileal conduit) yesterday. Which postoperative assessment finding should the nurse report to the healthcare provider (HCP) immediately?

- ✗ A. Mucous strings floating in the drainage.
- ✗ B. Red edematous stomal appearance.
- ✓ C. Stomal output of 40 mL in the last hour.
- ✗ D. Liquid brown drainage from stoma.

Explanation

A. Mucous strings floating in the drainage are expected after a ureteroileostomy because the ileal segment produces mucus. This is a normal finding and does not require immediate intervention.

B. A red, edematous stoma is a typical postoperative appearance within the first few days after surgery. Mild swelling and redness are expected due to surgical trauma and inflammation. Continuous monitoring is necessary, but it does not require immediate reporting.

C. Stomal output of 40 mL in the last hour is critically low and should be reported immediately. Normal ileal conduit output is typically 30–60 mL per hour, but a sudden decrease in urine output may indicate obstruction, dehydration, or impaired renal function. Prompt assessment and intervention are necessary to prevent complications such as kidney injury.

D. Liquid brown drainage from the stoma is consistent with normal urine output containing intestinal mucus and is expected from an ileal conduit. This finding is not a cause for concern and does not require immediate action.

The client demonstrates effective epidural anesthesia by Fetal heart rate ×, Maternal comfort ×, and No respiratory distress ×.

Answer and Explanation

Correct Answer:

Dropdown 1: **Progression of labor**

Dropdown 2: **Pain relief**

Dropdown 3: **Vital signs**

Pain relief: One of the primary goals and indications of effective epidural anesthesia is significant reduction or elimination of pain associated with labor contractions, as reflected in the patient asking for and receiving the epidural to manage increasing pain levels.

Progression of labor: Effective epidural anesthesia should allow the labor to progress without adding undue stress or causing significant delays. Monitoring cervical dilation and effacement as well as the baby's descent (station) helps determine if labor is progressing normally even after epidural administration.

Vital signs: Stable vital signs are important indicators that the epidural anesthesia is not causing adverse effects such as severe hypotension or bradycardia, which can sometimes occur with regional anesthesia due to the blockade of sympathetic nerves. Regular monitoring and stability of these signs are crucial for demonstrating effective and safe epidural anesthesia management.

A client who weighs 176 pounds receives a prescription for enoxaparin sodium 1.5 mg/kg/day subcutaneously. The medication is available in 120 mg/0.8 mL prefilled syringe. How many mL should the nurse administer? (Enter numerical value only.)
- First, convert the client's weight from pounds to kilograms: 176 pounds ÷ 2.2 = 80 kg.
- Next, calculate the total daily dosage in milligrams: 1.5 mg/kg/day × 80 kg = 120 mg/day.
- Since the medication is available in a concentration of 120 mg/0.8 mL, the client requires a full syringe of 0.8 mL for their daily dosage.

56. The nurse is caring for a client with a history of coronary artery disease who reports waking up with a sudden onset of viselike chest pressure. The client reports that the pain decreases at rest but continues to feel a constant mid-chest pressure. The nurse should perform which intervention in the immediate management of the client?

✓ A. Apply oxygen via nasal cannula and titrate to keep oxygen saturation above 93%.

× B. Initiate dim lighting, lower alarm volumes, and control traffic in and out of the room area.

× C. Determine the presence of ST-elevations or non-ST-elevations on electrocardiogram.

× D. Verify troponin level assessments are scheduled every 3-6 hours for a series of three.

Explanation

A. Apply oxygen via nasal cannula and titrate to keep oxygen saturation above 93%: Administering oxygen helps ensure adequate oxygenation to the heart tissue, which is essential in managing potential acute coronary syndrome symptoms, especially with sudden chest pain.
B. Initiate dim lighting, lower alarm volumes, and control traffic in and out of the room area: While this might improve the client's environment, it does not address the immediate need for assessing and managing potential acute coronary syndrome.
C. Determine the presence of ST-elevations or non-ST-elevations on electrocardiogram: Although this is important, oxygen therapy should be initiated first to stabilize the client while further diagnostic tests are performed.
D. Verify troponin level assessments are scheduled every 3-6 hours for a series of three: This is part of ongoing monitoring and not the immediate management of acute symptoms.

A mother runs into the emergency department with a toddler in her arms and tells the nurse that her child got into some cleaning products. The child smells of chemicals on the hands, face, and on the front of the child's clothes. After ensuring the airway is patent, which action should the nurse implement first?

- ✗ A. Determine type of chemical exposure.
- ✗ B. Obtain equipment for gastric lavage.
- ✗ C. Call poison control emergency number.
- ✓ D. Assess child for altered sensorium.

Explanation

A. Determine type of chemical exposure: Identifying the chemical is important but not the immediate first step. The priority is to assess the child's condition to determine if there are any acute symptoms or need for emergency intervention.
B. Obtain equipment for gastric lavage: Gastric lavage might be needed depending on the exposure and timing, but assessing the child's current condition takes precedence to determine the severity of the exposure.
C. Call poison control emergency number: While this is an important step, the immediate priority is to assess the child for any symptoms or complications from the exposure before taking further actions.
D. Assess child for altered sensorium: This is the first step to determine if the child is showing signs of distress or toxicity from the exposure, which will guide subsequent actions and interventions.

History and Physical | **Nurses' Notes** | Flow Sheet | Orders | Imaging Studies

1915

Client arrives via personal car to emergency department with facial drooping and garbled speech.
1925

Peripheral IV placed. Sodium chloride infusion started at 50 mL/hour. 1928
Neurological Assessment

- Alert and oriented Pupils equal and reactive

.Left sided facial droop 2025
Left side hand grasp strength slightly diminished

Left lower limb strength slightly diminished Speech difficult to understand Neurological assessment performed.
2040

Neurological assessment performed.

The nurse administered tPA and conducted neurologic assessments every 15 minutes during the infusion. The tPA infusion finished and the nurse performed neurologic assessments every 30 minutes for the 6 hours following the administration. The client was noted to be stable with unchanged neurologic assessments. The nurse begins to plan care for the client's recovery and identifies interdisciplinary team members who can assist with the client's recovery.

What interdisciplinary team member(s) should assist the client in recovery? Select all that apply.

✓ ☐ A. Case Manager

✓ ☐ B. Occupational Therapist

✓ ☑ C. Speech Therapist

✗ ☑ D. Respiratory Therapist

☐ E. Chief Nursing Officer

☐ F. Medical Assistant

✗ ☑ G. Pharmacy Technician

✓ ☑ H. Physical Therapist

An adult client is admitted to the psychiatric unit because of a daily, complex handwashing ritual that takes two hours or longer to complete. The client worries about staying clean and refuses to sit on any of the chairs in the day area. This client's handwashing is an example of which clinical behavior?

- ✗ A. Phobia
- ✗ B. Obsession.
- ✓ C. Compulsion.
- ✗ D. Addiction.

Explanation

A. Phobia.
A phobia is an irrational fear of a specific object, situation, or activity that leads to a desire to avoid it. The client's behavior is more characteristic of a compulsion rather than a phobia.

B. Obsession.
An obsession is an intrusive, unwanted thought, image, or urge that causes significant anxiety.
While the client's fear of contamination could be an obsession, the handwashing itself is a compulsion.

C. Compulsion.
This is the correct answer because a compulsion is a repetitive behavior or mental act that a person feels driven to perform in response to an obsession. The client's excessive handwashing ritual is a classic example of a compulsion.

D. Addiction.
Addiction involves a compulsive need for and use of a habit-forming substance or behavior, typically involving a sense of euphoria or pleasure, which is not applicable to the client's behavior.

Arterial blood gas results reviewed. The client's respiratory rate is 16 breaths/minute, and the ventilator is set at 14 breaths/minute. The breath sounds were diminished in the left lower lobe.

Crackles noted throughout. Notified the healthcare provider of the results of the blood gas and assessment findings.

Laboratory test	0815	0930	Reference range
pH	7.21	7.37	7.35 to 7.45
PaO2	82mmHg	94	80 to 100 mm Hg
PaCO2	58mmHg	52	35 to 45 mm Hg
HCO3	25mEq/L	29mEq/L	21 to 28 mEq/L

Based on the assessment and blood gas results, which 3 orders should the nurse expect from the healthcare provider?

- [x] A. Give a bolus of 1,000 mL 0.9% sodium chloride
- [ ] B. Repeat blood gas in 1 hour
- [ ] C. Place the client in a prone position
- [x] D. Perform endotracheal suctioning
- [x] E. Chest x-ray now
- [ ] F. Administer inhaled corticosteroid

A client has a prescription for the insertion of a nasogastric tube to low intermittent suction. When inserting the nasogastric tube, the nurse observes an immediate return of "coffee ground" drainage. Which action should the nurse implement?

- ✗ A. Connect the nasogastric tube to high continuous suction.
- ✓ B. Clamp the nasogastric tube and contact the healthcare provider.
- ✗ C. Connect the nasogastric tube to suction as prescribed.
- ✗ D. Immediately remove and then reinsert the nasogastric tube.

Explanation

A. Connecting the nasogastric tube to high continuous suction without further assessment or intervention is not appropriate and could exacerbate the situation.
B. Clamping the nasogastric tube and contacting the healthcare provider is the correct action. "Coffee ground" drainage can indicate the presence of blood in the stomach, which may require further evaluation and intervention by the healthcare provider.
C. Connecting the nasogastric tube to suction as prescribed without addressing the presence of "coffee ground" drainage is not appropriate. It's important to assess the significance of this finding before proceeding with suctioning.
D. Immediately removing and then reinserting the nasogastric tube may not be necessary and could increase the risk of trauma or complications. It's important to assess the situation further and involve the healthcare provider in decision-making.

The nurse is providing postoperative care for an adolescent who underwent a left leg amputation due to osteosarcoma.

The adolescent reports experiencing phantom limb pain.

Which non-pharmacological intervention should the nurse provide?

✓ A. Reassure that this can be a normal post-surgical sensation.

× B. Guide in moving the non-affected limb to override the sensation being experienced.

× C. Explain that the sensations of tingling and pain are not real.

× D. Affirm that a prosthetic with physical therapy will gradually improve the symptoms.

Subject	Correct / Total Pts	Score	Avg. Score
Adult Health	26 / 41	63%	72%
Child Health	22 / 30	73%	70%
Fundamentals	14 / 16	88%	61%
Management of Care	10 / 12	83%	68%
Maternal & Newborn Health	17 / 24	71%	55%
Mental Health	29 / 33	88%	71%
Pharmacology	9 / 12	75%	60%

Calculator Settings Mark for Review

Diagnostic Studies

1100:

© Bootcamp.com

The nurse is reviewing the client's Diagnostic Studies from 1100.

Which of the following actions should the nurse take?

1. Assess cervical dilation.
2. Stop the oxytocin infusion.
3. Prepare for imminent delivery.
4. Obtain an intrauterine pressure catheter.

Incorrect

Credit	0 / 1
Answered Correctly	47%
Scoring Rule	0 / 1 Scoring
Time Spent	01:03

Explanation

The neonatal intensive care nurse is caring for a newborn just delivered with a myelomeningocele.

Which of the following actions should the nurse take **first**?

1. Administer IV antibioitics.
2. Measure head circumference.
3. Assess client's range of motion.
4. Place the client in prone position.

Incorrect

Credit	0 / 1
Answered Correctly	74%
Scoring Rule	0 / 1 Scoring
Time Spent	01:11

Explanation

Myelomeningocele

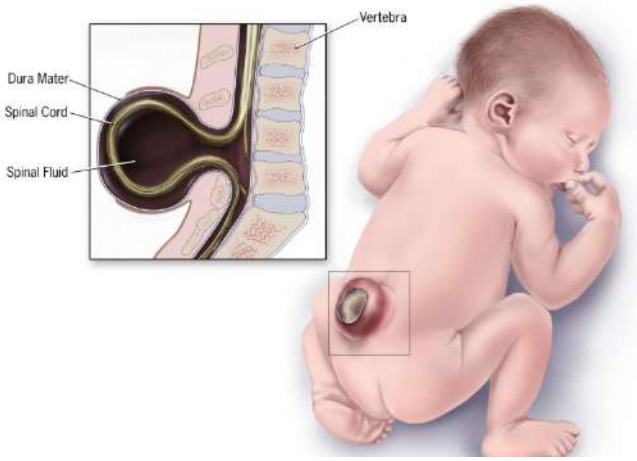

The following scenario applies to the next **6** items.

Item 1 of 6
The nurse cares for a 28-year-old pregnant client.

Health History | **Assessment** | **Vital Signs**

A 28-year-old client who is 38 weeks pregnant and a G4P2 arrived at the labor and delivery unit reporting leakage of vaginal fluid that started 1 hour ago. Fetal heart rate is 142 beats per minute via doppler. The client reports occasional burning epigastric pain. She has a headache but denies visual disturbances. She is not currently experiencing contractions. Client reports having a vaginal swab performed yesterday to test for chlamydia; results are still pending. Cervical exam yesterday showed the cervix was closed and 40% effaced.

Which of the following findings requires **immediate** follow-up? **Select all that apply.**

1. Headache
2. Epigastric pain
3. Systolic murmur
4. Leaking clear vaginal fluid
5. Possible chlamydia infection
6. Yellow, odorless vaginal discharge

Incorrect

Credit	0 / 1
Answered Correctly	Collecting data...
Scoring Rule	+ / - Scoring
Time Spent	03:20

Item 3 of 6
The nurse cares for a 28-year-old pregnant client.

Health History	Assessment	Vital Signs	Nurses' Notes	Laboratory Results

0300: Client's nitrazine test is positive.

0830: Contractions every 7 minutes; cervix 2 centimeters dilated and 60% effaced. Minimal FHR variability noted, and uterine contractions are palpated as weak. Health care provider placed an intrauterine pressure catheter and fetal scalp electrode. Client refusing oxytocin administration at this time.

0900: Client is 3 centimeters dilated. Client continues to refuse oxytocin augmentation of labor. Uterine contraction pain 7/10. Minimal FHR variability.

The nurse reviews the Nurses' Notes and Laboratory Results from 0900.

The nurse should **first** address the

1. oxytocin refusal
2. pain assessment
3. chlamydia test results ✓
4. fetal heart rate pattern ✗

Incorrect

Credit	0 / 1
Answered Correctly	35%
Scoring Rule	0 / 1 Scoring
Time Spent	01:15

Explanation

Calculator Settings Mark for Review

The nurse in a community-based setting is teaching clients about the prevention of Lyme disease.

Which of the following information should the nurse include?

1. ~~"Dark clothing should be worn when outside."~~
2. ~~"Use an insect repellent that contains DEET while outside."~~
3. "If you are bit by a tick, you should monitor for a diffuse, pinpoint, red rash."
4. "If you are bit by a tick, leave it in place until you can get medical assistance."

Incorrect

Credit	0 / 1
Answered Correctly	66%
Scoring Rule	0 / 1 Scoring
Time Spent	01:16

Explanation

Lyme disease is an infection caused by *Borrelia burgdorferi* bacteria that is transmitted through an infected deer tick bite, most often in the summer months in heavily wooded areas.

Lyme disease causes an **inflammatory immune response** characterized by **flu-like symptoms** (e.g., fever, headache, neck stiffness, joint pain, and fatigue). If left untreated, these symptoms can become **chronic and debilitating**.

Lyme disease prevention focuses on **tick bite prevention**, including:

- Using **insect repellent containing diethyltoluamide (DEET),** which effectively deters ticks **[Choice 2]**.
- Wearing long sleeves and pants tucked into shoes to prevent ticks from getting on the skin.
- Performing full-body inspections of self and pets after going outside to assess for ticks.

Incorrect:

Ultimate NCLEX Clinical ... | Ultimate NCLEX Clinical ... | NCLEX Bootcamp | Create | (9+) NCLEX Prep Hub (A... | (9+) NCLEX Rationale Sy... | notion alternatives with ...
app.bootcamp.com/nclex/custom-test
Bookmarks | WhatsApp | YouTube | Netflix | Amazon.com. ... | (9+) NCLEX st... | Academic - Ac... | Claude | ChatGPT | Google Gemini | Homepage - ... | Paraphrasing ... | Google Docs | iLovePDF | O...

The nurse asks a nursing student to identify breastfeeding contraindications.

Which of the following situations should the student nurse include as contraindications to breastfeeding? **Select all that apply.**

✓ 1. A newborn is diagnosed with galactosemia.

✗ 2. A newborn is diagnosed with phenylketonuria.

✓ 3. The mother has untreated, active tuberculosis.

4. ~~A client is in a drug treatment program that takes methadone.~~

5. ~~A client is receiving a blood transfusion after a postpartum hemorrhage.~~

Partial Credit

Credit	1 / 2
Avg Points Scored	Collecting data...
Scoring Rule	+ / - Scoring
Time Spent	00:50

Explanation

Breastfeeding promotes bonding and attachment while offering health benefits for the mother and newborn (e.g., decreased maternal risk for breast cancer, decreased infection risk in newborn). Breastfeeding is promoted unless there are **contraindications:**

- If the newborn is diagnosed with **galactosemia**, **human milk is contraindicated [Choice 1]**. In galactosemia, the body lacks the ability to break down the sugar galactose, causing a build-up in the blood and neurological complications (e.g., lethargy, seizures).
- A mother with an **untreated, active tuberculosis** (TB) infection should not breastfeed to **prevent newborn exposure [Choice 3]**. The mother can begin breastfeeding after being treated for TB for 2 weeks.

Incorrect:

A newborn diagnosed with phenylketonuria
Phenylketonuria (PKU) causes a buildup of the protein phenylalanine in the blood, as the body lacks the necessary enzyme to break it down. Dangerous levels cause neurological damage, so a lifelong phenylalanine-free diet is required. Breastmilk has lower phenylalanine concentrations than formula, making it safe to breastfeed.

app.bootcamp.com/nclex/custom-test

NCLEX-RN Test (Tutored, Untimed) | Bootcamp.com | 00:35:15 | Question 8 of 40

Calculator | Settings | Mark for Review

The charge nurse has received a change-of-shift report on the following clients in labor.

It would be a **priority** for the nurse to follow up with the laboring client

1. who is 38 years old and has a history of cesarean section
2. who has a classical incision from a previous cesarean section
3. who is 42 weeks pregnant and delivered a baby via cesarean section 2 years ago
4. who has an estimated fetal weight >8 lb 13 oz (4,000 g) and history of previous cesarean section

Incorrect

Credit	0 / 1
Answered Correctly	Collecting data...
Scoring Rule	0 / 1 Scoring
Time Spent	01:32

Explanation

Transverse vs. Classical Incision for Cesarean Section

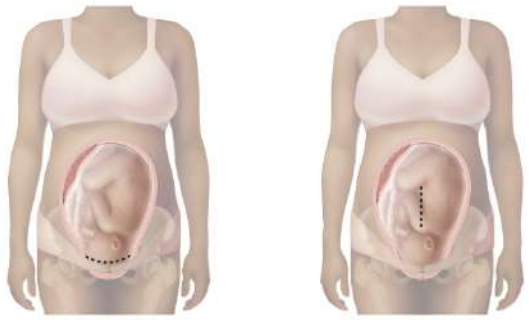

Transverse incision

- **Most common** cesarean section incision
- Lower risk for future uterine rupture

Classical incision

- Less common
- Performed when transverse incision is **contraindicated** (e.g., high fetal presentation) or **difficult** (e.g., transverse lie)
- **Increased risk for uterine rupture** with subsequent pregnancies and labor

© Bootcamp.com

End | Pause | Learning | Reviewing | Mastered | Previous | Navigate | Next

Monday April 6, 9:50 PM

The nurse is caring for a client who is receiving oxytocin for labor augmentation. The baseline fetal heart rate was 130 bpm on admission, and for the last 10 minutes, it was 165 bpm with no decelerations. The client has had nothing by mouth since drinking a diet soda this morning.

Which of the following interventions should the nurse perform?

✓ 1. Assess maternal temperature.

2. Assess the client's cervical dilation.

✗ 3. Discontinue oxytocin administration.

4. Educate on the effects of caffeine intake.

Incorrect

Credit	0 / 1
Answered Correctly	Collecting data...
Scoring Rule	0 / 1 Scoring
Time Spent	06:39

drug (e.g., cocaine, methamphetamines) and caffeine exposure (i.e., >200 mg/day) should also be considered. Therefore, the nurse should **assess the maternal temperature [Choice 1]**.

Maternal infection during labor requires prompt treatment with broad-spectrum antibiotics as intrauterine infection can harm the fetus (e.g., neonatal sepsis, intrauterine fetal demise) and client (e.g., septicemia).

Incorrect:

Assess the client's cervical dilation
Fetal tachycardia is not indicative of cervical dilation. Early decelerations indicate that the fetus is experiencing head compression, which occurs as the fetus descends into the maternal pelvis. This descent induces cervical dilation; therefore, the presence of early decelerations would prompt the nurse to assess cervical dilation.

Discontinue oxytocin administration
Oxytocin does not cause fetal tachycardia. Oxytocin, a uterine stimulant, increases contraction frequency, duration, and intensity, which can result in uteroplacental insufficiency if excessive stimulation occurs. The presence of late decelerations indicates uteroplacental insufficiency which would require oxytocin discontinuation.

A nurse is caring for a client with persistent mastitis infections.

Which of the following client findings increase the client's risk for mastitis? **Select all that apply.**

- [ ] A. Wears an underwire bra daily
- [x] **B. Reports pain during breastfeeding**
- [ ] C. Reports newborn was born tongue-tied
- [ ] D. Massages breasts before each feeding
- [x] **E. Eats breakfast at a fast food restaurant every morning**
- [x] F. Trying to decrease number of feedings by one session per week

Partial Credit

Credit 1 / 4

The nurse has taught a client with an ectopic pregnancy who is receiving methotrexate.

Which of the following statements by the client would indicate a correct understanding of the teaching?

A. "This medication will help prevent ectopic pregnancy in the future."

B. "Weekly β-hCG measurements are obtained to monitor for cancer."

C. "Folic acid supplements will help prepare my body for another pregnancy."

D. **"My partner and I will use contraception until my β-hCG levels are undetectable."**

Correct

Credit 1 / 1

The nurse is caring for four postpartum clients.

Which of the following clients should the nurse see **first**?

A. Client who delivered 1 day ago experiencing scant reddish-brown purulent lochia

B. Client who delivered 1 hour ago experiencing moderate vaginal bleeding and is receiving oxytocin IV

C. Client who delivered 8 hours ago experiencing increased vaginal bleeding while breastfeeding

D. Client who delivered 12 hours ago who experienced a gush of vaginal blood while ambulating for the first time

Incorrect

Credit 0 / 1

the client experiencing scant reddish-brown purulent lochia **[Choice 1]**.

Incorrect:

Moderate vaginal bleeding and receiving oxytocin IV

More frequent assessments are indicated in the first few hours following delivery; however, *moderate bleeding* is expected in the *immediate postpartum period*. Additionally, this client receives oxytocin, a uterotonic medication that promotes uterine contractions and slows uterine bleeding.

Increased vaginal bleeding while breastfeeding

Clients can expect lochia flow to increase with *breastfeeding* because it stimulates the release of *oxytocin*, *promoting uterine contractions*. As the uterus contracts, lochia is expelled. Urgent follow-up would be indicated if increased bleeding continu

Gush of vaginal blood while ambulating

“I have sharp pain in my groin”

As the uterus expands during pregnancy, it causes *nerve compression and stretching of ligaments* (e.g., groin). This commonly presents as sharp groin pain and shooting pains down the leg (i.e., sciatica). If pain becomes severe or persistent, further evaluation is needed.

Vital Signs

	0300	0900
T	97.9 F (36.1 C)	100.2 F (37.8 C)
BP	110/72	115/75
P	88	98
RR	20	20
Pulse oximetry reading	97% room air	98% room air

The nurse assesses the Vital Signs of a postpartum client who gave birth 6 hours ago.

Which intervention should the nurse perform **first**?

A. Apply ice packs to the client's head and neck.

The nurse assesses the Vital Signs of a postpartum client who gave birth 6 hours ago.

Which intervention should the nurse perform **first**?

- A. Apply ice packs to the client's head and neck.
- B. Recheck the client's temperature in 30 minutes.
- C. Fill the client's water pitcher and encourage her to drink.
- D. Obtain an order for a complete blood count and blood cultures.

Incorrect

Credit	0 / 1
Scoring Rule	0 / 1 Scoring
Answered Correctly	Collecting data...

with a new diagnosis of human immunodeficiency virus (HIV) infection who is scheduled for induction next week. The client is tearful and asks the nurse how this will affect her labor and postpartum plan.

Which of the following statements should the nurse include in the discussion? **Select all that apply**.

- [ ] A. "A cesarean section is not always necessary."
- [ ] B. "The newborn will have to be bathed immediately after delivery."
- [ ] C. "You will have to pump if you want to provide your child with breastmilk."
- [ ] D. "You will receive confirmation of the newborn's HIV status before discharge."
- [x] E. "The newborn must remain in the nursery for monitoring during the hospital stay."

F. "Antiretroviral therapy will be administered to the newborn, regardless of your viral load."

G. "Intravenous antiretroviral therapy will be administered during labor if your viral load is elevated."

Partial Credit

Credit	1 / 4
Average Score	Collecting data...
Scoring Rule	+ / - Scoring
Time Spent	01:18

Explanation

HIV *(human immunodeficiency virus)*is a sexually-transmitted disease that attacks the CD4+ T cells, suppressing the body's immune response. It can be transmitted from mother to child transplacentally, during birth, or by breast milk. Treatment for the pregnant client depends on the client's viral load

Health History

0730: A 17-year-old client is being seen at the obstetrician's office at 31 weeks gestation. She expresses feeling constant, mild lower abdominal cramps. Client experienced diarrhea yesterday evening and had bright pink vaginal spotting this morning after exercising. Client described an episode of urinary incontinence yesterday morning.

The nurse is caring for a pregnant client and reviews the Health History from 0730.

Select words from the choices below to fill in the blank in the following sentence.

The nurse knows the client is **most** likely experiencing placenta previa ✕ .

Explanation

Preterm labor is characterized by regular uterine contractions that can be described as pelvic pressure or cramping (i.e., **constant, mild lower abdominal cramps**), occur at <37 weeks gestation, and cause cervical changes.

Clients may experience **diarrhea** preceding labor related to a rise in estrogen, drop in progesterone, and release of prostaglandins. Ruptured membranes suggest potential labor, and the gush of fluid that occurs with rupture may be perceived by the client as **urinary incontinence**. Cervical changes (e.g., effacement [thinning]) cause bloody show (i.e., **bright red vaginal bleeding**).

Therefore, **the nurse knows the client is most likely experiencing preterm labor.**

Incorrect:

Gastroenteritis

Nurses' Notes

1045: Client admitted this morning for induction of labor with oxytocin. Oxytocin has slowly been increased, and contractions are now every 2-3 minutes. Client is fully dilated, and the fetal head is at the +3 station. Fetal head is assessed as right occiput anterior. Client experiencing perineal pressure.

The nurse is caring for a client in labor. The nurse reviews the Nurses' Notes from 1045.

Which intervention is appropriate at this time?

A. Reposition the client to adjust fetal position.

B. Increase oxytocin rate to strengthen contractions.

at the +3 station. Fetal head is assessed as right occiput anterior. Client experiencing perineal pressure.

The nurse is caring for a client in labor. The nurse reviews the Nurses' Notes from 1045.

Which intervention is appropriate at this time?

A. Reposition the client to adjust fetal position.

B. Increase oxytocin rate to strengthen contractions.

C. Notify the health care provider of the current assessment.

D. Ask the client to notify the nurse when she feels the urge to push.

Incorrect

Credit 0 / 1

Nurses' Notes

1330: Client being seen for a routine obstetric appointment. The client reports experiencing frequent mild headaches and nausea with vomiting every time she eats. She also notes that she has not felt any fetal movement. The client has had a stuffy nose for several weeks and bleeding gums when she brushes her teeth.

The nurse reviews the Nurses' Notes for a client who is 12 weeks pregnant.

Which of the following client findings are concerning? **Select all that apply**.

- [ ] ~~A. Nausea~~
- [x] **B. Vomiting**

gums when she brushes her teeth.

The nurse reviews the Nurses' Notes for a client who is 12 weeks pregnant.

Which of the following client findings are concerning? **Select all that apply**.

- [ ] ~~A. Nausea~~
- [x] **B. Vomiting**
- [ ] C. Headaches
- [ ] D. Bleeding gums
- [ ] E. Nasal stuffiness
- [x] F. No fetal movement felt

Incorrect

Credit 0 / 1

The nurse is caring for a client with uterine inversion.

Which of the following actions should the nurse take **first**?

A. Quantify vaginal blood loss

B. Administer IV pain medication

C. Assess fundal height and tone

D. Prepare for manual uterine repositioning

Incorrect

Credit	0 / 1
Scoring Rule	0 / 1 Scoring
Answered Correctly	34%
Time Spent	00:21

Explanation

The nurse is caring for a client who is undergoing an amniotomy.

Which of the following findings would require follow-up?

- A. Blood-colored amniotic fluid
- B. Fetal station changes from 0 to +1
- C. Early fetal heart rate decelerations
- D. White specks present in amniotic fluid

Incorrect

Credit	0 / 1
Scoring Rule	0 / 1 Scoring
Answered Correctly	52%
Time Spent	00:41

Explanation

The charge nurse receives report from the night shift charge nurse.

Which of the following clients should the charge nurse assess **first**?

A. A client who is 38 weeks pregnant experiencing contractions that last for 2 minutes

B. A client who is 37 weeks pregnant with pruritic lesions on the abdomen and arms that started a few days ago

C. A client who is 39 weeks pregnant whose membranes ruptured 18 hours ago with a new baseline fetal heart rate of 165

D. A client who is 40 weeks pregnant experiencing 10/10 intermittent pain in her lower right abdomen following epidural placement

Answered Correctly	Collecting data...
Time Spent	01:09

Explanation

During labor, uterine contractions occur in regular intervals and last for <90 seconds. During contractions, uterine arteries are compressed and cannot refill the placenta with oxygenated blood. Uterine contractions that occur too frequently (i.e., uterine tachysystole) or are prolonged in duration (i.e., **lasting >90 seconds**) prevent uterine rest between contractions and can cause fetal hypoxemia **[Choice 1]**. Factors that cause excessive uterine stimulation (e.g., tachysystole, prolonged contractions) increase the risk for uterine rupture and placental abruption and require immediate intervention.

Incorrect:

37 weeks pregnant with pruritic lesions on abdomen and arms

39 weeks pregnant and ruptured membranes 18 hours ago

This client's prolonged rupture of membranes and new fetal tachycardia (i.e., FHR >160 for ≥10 minutes) may indicate chorioamnionitis, an intrauterine infection. This client might require broad-spectrum antibiotics; however, this does not take priority over possible fetal hypoxemia.

40 weeks pregnant experiencing intermittent pain in abdomen after epidural placement

Occasionally epidural placement requires readjustment or redosing when pain is not relieved. This does not take priority over potential fetal hypoxemia.

Nurses' Notes

1100: Client is 39 weeks pregnant and laboring. Baseline fetal heart rate 130. History of polyhydramnios this pregnancy.

1230: Cervix is 3 centimeters dilated, 50% effaced. The fetal station is -1. Membranes spontaneously ruptured and fetal heart rate is now 95 with minimal variability.

The nurse is caring for a client who is 39 weeks pregnant and experiencing regular uterine contractions every 4-5 minutes. The nurse reviews the Nurses' Notes from 1100 and 1230.

Which of the following interventions should the nurse perform **first**?

- A. Place the client in Trendelenburg
- B. Provide a wedge under the left hip

ruptured and fetal heart rate is now 95 with minimal variability.

The nurse is caring for a client who is 39 weeks pregnant and experiencing regular uterine contractions every 4-5 minutes. The nurse reviews the Nurses' Notes from 1100 and 1230.

Which of the following interventions should the nurse perform **first**?

- A. Place the client in Trendelenburg
- B. Provide a wedge under the left hip
- C. Notify the health care provider of the fetal heart rate
- D. Insert fingers into the vagina and assess for the presenting part

Incorrect

Credit	0 / 1
Scoring Rule	0 / 1 Scoring

Explanation

When the fetal head is not well engaged in the pelvis (e.g., negative fetal station) and a large gush of amniotic fluid (e.g., polyhydramnios) occurs, the umbilical cord can deliver prematurely. An umbilical cord prolapse is an obstetric emergency.

When cord prolapse occurs, the presenting part (e.g., fetal head) compresses the umbilical cord preventing blood flow to the fetus which causes fetal heart rate (FHR) decelerations (i.e., 95 bpm) and can lead to fetal hypoxia. The fetal head must be lifted off the umbilical cord to reduce compression and improve oxygen delivery to the fetus. Therefore, the nurse should first **insert fingers into the vagina and assess for the presenting part** to lift the head and reduce compression **[Choice 4]**.

Incorrect:

The nurse and new graduate nurse are preparing a client for an amniocentesis who is 15 weeks pregnant and has a blood type of A (-).

Which statement indicates that the new graduate nurse understands this procedure?

A. "This client does not require Rh immunoglobulin."

B. "Fluid leakage from the vagina is expected following this procedure."

C. "I will teach the client to monitor for increased leg swelling after the procedure."

D. "Abdominal pain is not expected and should be reported to the healthcare provider."

Incorrect

Credit 0 / 1